

Enhancement of survival of stored dopaminergic cells and promotion of graft survival by exposure of human fetal nigral tissue to glial cell line–derived neurotrophic factor in patients with Parkinson’s disease

Report of two cases and technical considerations

IVAR MENDEZ, M.D., PH.D., ALAIN DAGHER, M.D., MURRAY HONG, PH.D., ADAM HEBB, B.SC., PAULA GAUDET, B.SC.O.T., ADAM LAW, M.D., SWARNA WEERASINGHE, PH.D., DAVID KING, M.D., JACQUES DESROSIERS, M.D., SULTAN DARVESH, M.D., PH.D., TANYA ACORN, M.SC., AND HAROLD ROBERTSON, PH.D.

Departments of Surgery (Neurosurgery), Medicine (Neurology), Anaesthesia, and Gynaecology, Dalhousie University and Queen Elizabeth II Health Sciences Centre; Neural Transplantation Laboratory, Department of Anatomy and Neurobiology, and Departments of Community Health and Epidemiology, and Pharmacology, Dalhousie University, Halifax, Nova Scotia, Canada; McConnell Brain Imaging Centre, Montreal Neurological Institute, McGill University, Montreal, Quebec, Canada

✓ The authors have studied the ability of glial cell line–derived neurotrophic factor (GDNF) to promote survival of human fetal dopaminergic tissue after a storage period of 6 days and subsequent implantation into the human putamen. The results indicate that GDNF promotes survival of stored dopaminergic cells. Cells stored without GDNF had a 30.1% decrease in survival time compared with those exposed to GDNF. Two patients with Parkinson’s disease received bilateral putaminal implants of fetal dopaminergic cells exposed to GDNF for 6 days and showed enhancement of graft survival as assessed by positron emission tomography scanning. A mean increase of 107% in putaminal fluoro-dopa uptake from baseline values was observed 12 months postgrafting.

KEY WORDS • Parkinson’s disease • glial cell line–derived neurotrophic factor • neural transplantation • stereotactic neurosurgery

NEURAL implantation of fetal VM tissue has been studied for the past two decades as a potential surgical strategy for the treatment of PD. Clinical trials have been conducted in several centers worldwide, with more than 200 patients receiving fetal tissue implants into the striatum.^{21,24,28,33} Although the improvement in these patients has been promising, clinical efficacy has been limited and has not reached sufficient levels for this strategy to be used routinely as a therapeutic procedure in PD. Survival of implanted dopaminergic neurons has been demonstrated on PET scanning^{5,29,38} and postmortem histological examination.¹³ Survival of implanted cells has been suboptimal. At best with current techniques, 5 to

10% of grafted cells survive the implantation procedure.^{12,14} Reinnervation of the targeted putamen also appears limited to 30 to 50% of its volume.¹³ This poor cell survival combined with restricted reinnervation of the treated putamen are considered limiting factors for clinical efficacy of fetal tissue implantation for PD.^{21,24,33}

Improving graft survival and fiber outgrowth has been the focus of numerous animal studies. Decreasing implantation trauma by using smaller cannulas,²³ exposure to scavenger steroid compounds (lazaroids),²² or antiapoptotic agents (caspase inhibitors)³¹ have shown benefits in improving dopaminergic graft survival. Recently, the use of neurotrophic factors to increase graft survival has been reported.^{34,40} A particularly promising neurotrophic agent is the recently discovered GDNF, which acts specifically on dopaminergic neurons. This agent has been shown to substantially increase the survival and differentiation of dopaminergic neurons in vitro and in vivo.^{7,17,25} The use of GDNF to enhance survival of VM grafts has also been attempted and produced positive results. The infusion of

Abbreviations used in this paper: ADL = activities of daily living; BBB = blood–brain barrier; DMEM = Dulbecco’s modified Eagle’s medium; GDNF = glial cell line–derived neurotrophic factor; K_i = uptake constant; MR = magnetic resonance; PD = Parkinson’s disease; PET = positron emission tomography; TH = tyrosine hydroxylase; UPDRS = Unified Parkinson’s Disease Rating Scale; VM = ventral mesencephalic.

TABLE 1
Demographic factors and baseline scores in two patients who underwent VM tissue implantation for PD

| Case No. | Age (yrs), Sex | Duration of PD (yrs) | UPDRS Score (on/off) | Schwab-England Scale Score | Hoehn & Yahr Scale Score | Percent Off |
|----------|----------------|----------------------|----------------------|----------------------------|--------------------------|-------------|
| 1 | 56, M | 12 | 102/113 | 70/60 | 3/4 | 50 |
| 2 | 71, M | 17 | 77/97 | 90/80 | 2.5/2.5 | 50 |

GDNF into the brain of rats bearing dopaminergic grafts has resulted in increased cell survival and fiber outgrowth.^{8,32,35,39} Recently we demonstrated that storing VM tissue in 1 mg/ml of GDNF for 6 days improves cell survival and fiber outgrowth and promotes a faster recovery in rotational behavior in the rodent model for PD.^{1,20} Furthermore, we have observed that rats implanted with VM cell suspensions and exposed to GDNF showed improvement in more complex sensorimotor tests, which is a better reflection of the sensorimotor deficits experienced by humans.²⁰

Although the underlying reason for the poor survival of implanted fetal human dopaminergic neurons is not entirely known, it is likely that cell damage or death occurs prior to or during the implantation procedure. A recent investigation showed that most of the implanted dopaminergic neurons die within 24 hours postimplantation and that preincubation of these neurons with a combination of neurotrophic factors that included GDNF increased survival by 50%.⁴¹

In this study we demonstrate improved dopaminergic cell survival in human VM tissue exposed to GDNF. We also provide evidence of the feasibility of using human VM tissue for clinical implantation after it has been stored in GDNF for 6 days. We present the 1-year follow-up PET scans and report the clinical results in two patients with advanced PD who received bilateral putaminal grafts of VM tissue that had been exposed to GDNF before implantation.

Summary of Cases and Techniques

Patient Selection

Patients participating in this study were from the Dalhousie Movement Disorder Clinic at the Queen Elizabeth II Health Sciences Centre, Halifax, Nova Scotia, Canada. Inclusion criteria included a diagnosis of idiopathic PD made independently by two neurologists, preoperative PET scans consistent with PD, and progression of PD to at least a Hoehn and Yahr Stage 2.5. Patients must have responded well to levodopa from the onset of the disease, but maximum tolerated medication must no longer provide adequate relief of symptoms, or there must have been unacceptable side effects. Patients must have undergone detailed assessment in the Movement Disorder Clinic for at least 3 months before surgery, as defined by the Core Assessment Program for Intracerebral Transplantation.¹⁵ Patients were excluded from the study if their PD was secondary to progressive supranuclear palsy, multiple system atrophy, olivopontocerebellar atrophy, striatonigral

degeneration, corticobasal degeneration, dementia, cerebral trauma, neoplasia, central nervous system infection, cerebrovascular disease, neurological deficits secondary to exposure to toxins, or any underlying or accompanying medical condition that precluded surgery or immunosuppression. Patients were screened for serological evidence of infection with syphilis, hepatitis B and C, human immunodeficiency virus, cytomegalovirus, and human T-cell lymphotropic virus. Patient demographic information and baseline clinical parameters are shown in Table 1.

Patient Assessment

Preoperative and postoperative clinical assessments were performed on an outpatient basis at 3-month intervals in the Movement Disorder Clinic by using the UPDRS, Hoehn and Yahr staging, and the Schwab and England ADL scale, which are discussed in Fahn and Elton.⁴ Clinical parameters were tested and videotaped. All tests were conducted at maximum on/off periods as defined by the Core Assessment Program of Intracerebral Transplantation protocol. Video recordings were assessed by a neurologist in a blinded fashion. Throughout the trial, patients and caregivers maintained diaries that included a registry of medications and subjective on/off status. The Wilcoxon rank exact test for paired data was used in the statistical analysis.

Cell Suspension Preparation

Fetal VM tissue was obtained from women undergoing elective abortions in the pregnancy termination unit of our center; strict guidelines of a protocol approved by the University and Hospital ethical review boards were followed. There was no alteration in the indication, timing, and methodology of the abortion procedure. Fetal tissue was collected with maternal consent from human immunodeficiency virus-, human T-cell lymphotropic virus-, hepatitis B-, hepatitis C-, and syphilis-negative women undergoing elective abortion by suction curettage between the 6th and 9th week of gestation for reasons unrelated to this implantation procedure. Tissue was not used from women with fever, elevated white blood cell count, cultures positive for gonorrhea or chlamydia, detectable antibodies to cytomegalovirus, or herpes simplex virus.

Fetal ventral mesencephalons were dissected under sterile conditions and tissue samples from each specimen were prepared for aerobic and anaerobic culture. The ventral mesencephalons were then placed in storage for 6 days at 4°C in 2 ml of a low-Na⁺, phosphate-buffered, Ca⁺⁺-free storage medium^{1,20} consisting of: 30 mM KCl, 5 mM glucose, 0.24 mM MgCl₂, 10.95 mM NaH₂PO₄, 5 mM NaH₂PO₄, 20 mM lactic acid, 32.18 mM KOH, and 164.7 mM sorbitol, pH 7.4. Treated stored tissue received recombinant human GDNF (1 µg/ml storage medium).

Cell suspensions of VM tissue were incubated in 0.1% trypsin/0.05% DNase/DMEM at 37°C for 20 minutes and then rinsed four times in 0.05% DNase/DMEM. The tissue was then mechanically dissociated using successively smaller sterilized micropipettes until a chunky cell suspension was achieved. This suspension was not homogeneous and contained small aggregates of cells. A final concentration of approximately 100,000 cells/µl was used, with viabilities of 97 to 98% as determined using the

TABLE 2
Transplantation parameters in two patients who received VM tissue grafts

| Case No. | No. of Donors/Side | Concentration (cells/ μ l) | Viability (%) | Passes Per Side | Deposits Per Pass | Volume (cells per deposit) | Total Volume (cells per side) |
|----------|--------------------|--------------------------------|---------------|-----------------|-------------------|----------------------------|-------------------------------|
| 1 | rt 3, lt 3 | 100,000 | 97 \pm 1.3 | 4 | 4 | 2.5 μ l (250,000) | 40 μ l (4 million) |
| 2 | rt 4, lt 3 | 100,000 | 98 \pm 0.9 | 4 | 4 | 2.5 μ l (250,000) | 40 μ l (4 million) |

trypan blue dye exclusion method. Tissue from three to four fetuses was used for each implanted side (Table 2).

In Vitro Studies

To determine the number of TH-immunoreactive cells in VM tissue 6 days after storage with GDNF compared with tissue stored for 6 days without GDNF, eight human ventral mesencephalons (gestational age 6–9 weeks) were dissected. Each ventral mesencephalon was divided along the midline and each half was assigned to one of three groups: 1) control fresh preparation; 2) stored with GDNF (1 mg/ml for 6 days at 4°C); or 3) stored without GDNF.

Cell suspensions were prepared by incubating each piece of tissue in 0.1% trypsin and 0.05% DNase/DMEM for 20 minutes at 37°C and then rinsed four times in DNase/DMEM to stop trypsin activity. The tissue was mechanically dissociated by trituration in which successively smaller sterilized micropipettes were used until a chunky cell suspension was achieved. This suspension was centrifuged at 1000 rpm for 5 minutes and the cell pellet was resuspended in DMEM. The cell suspensions were plated onto 10 μ g/ml poly-L-lysine coated tissue culture wells at 200,000 cells/cm² in a serum-free medium that consisted of DMEM/F12 3:1, B27 2 ml/100 ml media, penicillin 100 U/ml, and streptomycin 100 μ g/ml.

Immunohistochemical studies for TH were conducted using 4% paraformaldehyde fixed slides. Briefly, cell cultures were quenched in 3% H₂O₂/10% MeOH for 10 minutes, followed by blocking for 1 hour with normal swine serum in 0.3% Triton-X100. Cell cultures were incubated overnight at room temperature in primary antibody followed by a swine anti-rabbit secondary antibody for 1 hour, followed by incubation in avidin-biotin complex for 1 hour and diaminobenzidine in H₂O₂ for 5 to 10 minutes. Cell cultures were double stained with cresyl violet to determine the proportion of TH-positive cells.

Cell counting was performed on cell cultures stained for TH immunoreactivity. Cell counts were made using an eyepiece grid (0.25 \times 0.25 mm divided into a 10 \times 10-mm grid), counting TH-positive cells and cresyl violet-stained non-TH positive cells within a fixed area. Sample areas were chosen using a randomized number generator that generated x and y coordinates within the total culture area. Because each ventral mesencephalon was divided in two halves and could only be assigned to two of three groups, the results were compared relative to the common treatment (stored with GDNF). Statistical analysis was performed using a t-test, assuming equal variances.

Surgical Procedures

The surgical implantation procedures were performed in two stages 4 to 6 weeks apart. On the day of surgery, pa-

tients received a local anesthetic and then were fitted with a Leksell stereotactic headframe. The stereotactic coordinates for targets in the postcommissural putamen were calculated using T₁-weighted MR images and a computerized stereotactic neurosurgery planning workstation.

Implantation of fetal tissue was performed with the patient receiving a local anesthetic and sedation with a combination of midazolam (0.25–1.0 mg bolus doses) and propofol (10- to 20-mg bolus followed by infusion at 15–40 μ g/kg/minute). A burr hole was placed at the level of the coronal suture and a customized cannula (outer diameter 0.8 mm) was inserted into four different targets approximately 3 mm apart in the postcommissural putamen. A 50- μ l Hamilton syringe fitted with a custom-made microinjector was used to load the cell suspension into the cannula. The cell suspension was deposited along each of four trajectories previously calculated on the patient's MR image. Four injections of approximately 2.5 μ l (250,000 cells) were made in each trajectory for a total of 10 ml per trajectory. Approximately 4 million cells were deposited in each postcommissural putamen (Table 2). The patients received 1 g Ancef intravenously before the skin incision was made and three more 1-g doses of Ancef intravenously every 8 hours postoperatively. The patients underwent follow-up MR imaging (1.5-tesla magnet, T₁- and T₂-weighted, axial, coronal, and sagittal images) 24 hours postsurgery to check for target accuracy, and were discharged from the hospital 48 hours after surgery.

Perioperative Management

Patients were started on immunosuppressive medication (cyclosporine A, 5–8 mg/kg/day) 2 weeks before their admission. Doses were tapered to 2 mg/kg/day and continued for 6 months. Immunosuppressive doses were adjusted on the basis of serum levels. Renal function was monitored closely to prevent immunosuppressive toxicity. Postoperatively, every effort was made to keep antiparkinsonian medications at their preoperative level and modifications were only made for clinical reasons.

Imaging Studies

The PET scans were obtained at the McConnell Brain Imaging Centre (Montreal Neurological Institute, McGill University, Montreal, Canada) before and after the implantation procedure. Imaging was performed on the PET scanner in three-dimensional mode, with a resolution of 5 mm full width at half maximum in all directions at the center of the field of view. Participants received 5 mCi of fluorodopa as a bolus injection into the antecubital vein over a 2-minute period. Their heads were immobilized within the aperture of the PET scanner by a form-fitting vacuum device. One hour before the scan, the patients re-

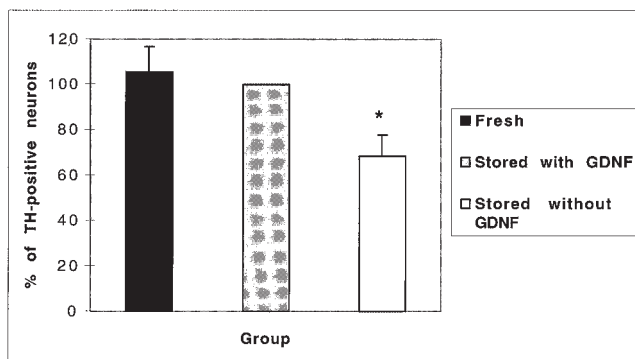


FIG. 1. Bar graph showing the percentage of TH-positive neurons in cell cultures of human VM tissue. Cell cultures were made of fresh VM tissue and tissue stored for 6 days with and without GDNF. The results were compared relative to the cell stored with GDNF. * $p = 0.006$.

ceived 150 mg carbidopa orally to prevent the peripheral breakdown of fluorodopa. On the day of the study, patients did not receive antiparkinsonian medications and they did not eat breakfast before the scan was obtained. After the injection of fluorodopa, PET data were acquired for 90 minutes in 27 timeframes of varying duration. In addition, all patients underwent high-resolution MR imaging (1.5-tesla magnet, T_1 -weighted images, mm^3) for the purpose of anatomical coregistration.

The PET scans were automatically realigned to MR images for each patient³ and then the regions of interest were drawn onto the MR image on the basal ganglia (caudate and putamen) and cerebellum. The cerebellum was used as a reference region to calculate the fluorodopa K_i by using the graphic method of Patlak and Blasberg.²⁶ In addition, maps were generated by calculating the K_i at each voxel. Striatal constants were taken of the putamen, caudate, and the grafted area. The PET scans were obtained preoperatively, 6 months, and 1 year after the last surgery. The Wilcoxon rank exact test for paired data was used in the statistical analysis.

Follow-up MR images with gadolinium enhancement were obtained at 6 months and 1 year postoperatively (T_1 - and T_1 -weighted axial, coronal, and sagittal images) to check for BBB disruption.

Sources of Supplies and Equipment

The recombinant human GDNF was purchased from Prepro Tech, Inc., Rocky Hill, NJ. The trypsin was acquired from Worthington, Freehold, NJ. The DNase and DMEM were obtained from Sigma, Chicago, IL. The B27 medium was purchased from Gibco, Burlington, ON, Canada. The rabbit anti-TH was acquired from Pel Freeze, Rogers, AR. The avidin-biotin complex was provided by Vector Dimension, Burlington, ON, Canada. The Leksell stereotactic headframe was purchased from Elekta AB, Stockholm, Sweden, as was the Surgiplan workstation. The Signa-Horizon MR imager and Philips Gyroscan high-resolution device were acquired from General Electric Medical Systems, Milwaukee, WI. The PET scanner (ECAT HR+) was obtained from Siemens, Erlangen, Germany.

Results

In Vitro Studies

Each ventral mesencephalon was divided into two halves and assigned to two of three groups (fresh, stored with, and stored without GDNF). The experimental group (stored with GDNF) was compared with the control groups (fresh, stored without GDNF). For the purpose of this comparison the group stored with GDNF was defined as 100%. The percentage of TH-immunoreactive cells in cultures of fresh tissue was $106 \pm 11\%$, which was not significantly different from the GDNF-treated group ($p = 0.59$). The proportion of TH-immunoreactive cells in cultures of tissue stored without GDNF was $69 \pm 9\%$. The survival of TH-positive cells in this group was 30.1% lower than in the GDNF-treated group and this difference was statistically significant ($p = 0.006$; Fig. 1).

Surgical Procedure

No conflicts were encountered between the procurement of fetal tissue from elective abortions and the implantation procedure. All cultures of fetal tissue were negative for the pathogens tested before the implantation surgery.

The two patients underwent bilateral implantation of fetal ventral mesencephalons tissue previously stored with $1 \mu\text{g/ml}$ GDNF for 6 days at 4°C . These patients tolerated the surgical procedures well and there were no intra- or perioperative complications. The brain MR images obtained 24 hours postsurgery demonstrated that the deposits were made at the desired targets in all cases. The MR images obtained with gadolinium enhancement performed at 6 months and 1 year postimplantation demonstrated no areas of enhancement, which indicated no BBB breakdown. The patients tolerated immunosuppression well; there were no significant adverse effects.

Fluorodopa Uptake on PET Scans

Preoperative PET scans confirmed that the two patients had decreased putaminal fluorodopa uptake consistent with the diagnosis of idiopathic PD.^{16,37} The mean preoperative uptake rates in the entire putamen were $30 \pm 12.4\%$ of age-matched normal controls. One year postoperatively, there was an increase in the mean putaminal fluorodopa uptake to $62.3 \pm 7.4\%$. This represented an increase of 107% from the preoperative values and was statistically significant ($p = 0.03$; Fig. 2A). The mean FD uptake in the grafted areas of the postcommisural putamen also increased from $31.6 \pm 6.9\%$ to $79 \pm 10.1\%$. This represented an increase of 149.7% and was statistically significant ($p = 0.03$). The mean fluorodopa uptake in the caudate increased from $38.3 \pm 7.6\%$ to $52.3 \pm 11.4\%$ 1 year after surgery, although this increase was only marginally significant ($p = 0.07$). The mean K_i values and percentage of change for the grafted area, putamen, and caudate are shown in Fig. 2B and C.

Clinical Outcomes

The pre- and postoperative (15-month follow up) scores for each patient are shown in Table 3. The total UPDRS scores in the on/off states for the patient in Case 1 im-

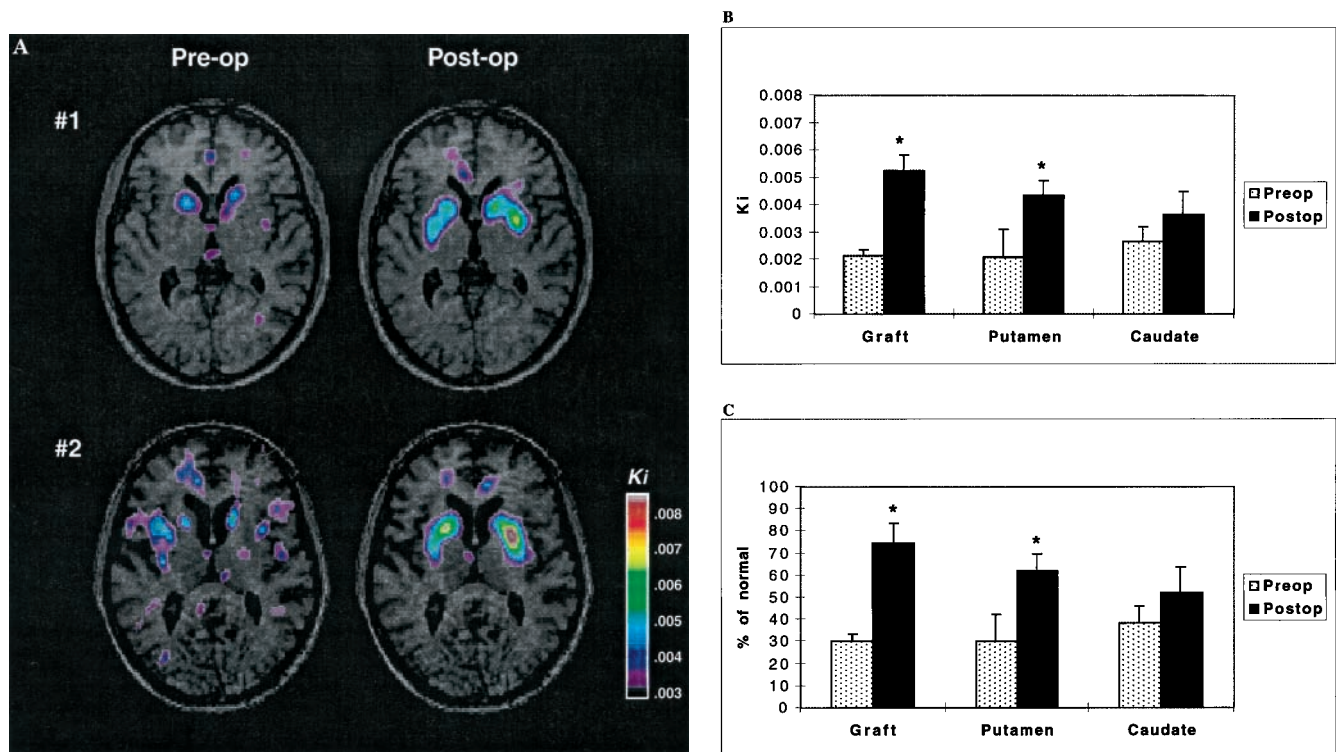


FIG. 2. A: Preoperative and 1-year postoperative PET scans realigned to MR images in two patients (1, 2) who underwent implantation with stored VM tissue exposed to GDNF. A significant increase in putaminal [¹⁸F]fluorodopa K_i was observed bilaterally in the two patients 1 year after implantation. B: Bar graph showing preoperative and 1-year postoperative mean regional [¹⁸F]fluorodopa K_i values. C: Bar graph showing percentage of change of normal uptake in the area of the graft, putamen, and caudate in the two patients reported. * p = 0.03.

proved from 102/133 at baseline to 63/72 postsurgery. For the patient in Case 2 the total UPDRS scores in the on/off states also improved from 77/97 at baseline to 66/71 postoperatively. The improvement in the total UPDRS scores was significant ($p < 0.05$) when the on/off scores for both patients were combined. The percentage of time in the off state decreased in both patients, from a baseline of 50% to 25% postoperatively. The Schwab and England scores in the on/off states improved in Case 1 from 70/60 at baseline to 90/70 postoperatively. In Case 2, these scores for the on/off states decreased from 90/80 at baseline to 70/60 postoperatively. This decrease in the Schwab and England scores in Case 2, which reflects the ADL, was attributed to the development of thyroiditis 12 months after implantation, which in turn affected his performance on the ADL assessment. The patient in Case 1 experienced a decrease in his levodopa requirements from 600 mg/day at baseline to 300 mg/day postsurgery. There was no change in levodopa dosage in the patient in Case 2.

Discussion

In this study we have demonstrated that the addition of GDNF during storage of human fetal VM tissue promotes survival of TH-positive neurons for up to 6 days and enhanced putaminal fluorodopa uptake in two patients who underwent fetal tissue implantation. Two of the crucial shortcomings of neural cell implantation for treatment of

PD are poor dopaminergic cell survival and limited host reinnervation by the implant. These limitations may be detrimental to the clinical efficacy of fetal tissue grafts for treating PD. It is likely that cell loss occurs at the time of tissue preparation, storage, and during implantation. Numerous strategies to enhance dopaminergic cell survival are currently under investigation. For example, decreasing the implantation trauma by using thinner cannulas and injecting smaller volumes appears to increase graft survival.²³ A number of compounds such as antioxidant agents (lazaroids),²² caspase inhibitors,³¹ and neurotrophic factors such as basic fibroblast growth factor,³⁴ brain-derived neurotrophic factor,⁴⁰ and GDNF^{8,32,35,38} have been shown to increase survival of dopaminergic grafts. In most cases these agents have been used at the time of implantation or instilled into the brain after graft implantation.^{8,35,39}

Storing VM tissue before implantation has been shown to be detrimental for cell survival in animal models.³⁰ Rats receiving grafts of fetal tissue stored for 5 days showed a decreased number of TH-positive cells. This decrease was even more marked in animals receiving grafts of tissue stored for 10 days.³⁰ In an effort to improve cell survival during the storage period, we have used GDNF in the storage of rat fetal VM tissue for 6 days at 4°C.^{1,20} Our experiments have demonstrated increased survival of implanted dopaminergic cells and a significant increase in fiber outgrowth and behavioral recovery in rats receiving implants of cell suspensions stored in GDNF. Although it is not

TABLE 3
Preoperative and postoperative (15-month follow up) scores
for each patient in the best on/worst off state

| Assessment | Case 1 (on/off) | Case 2 (on/off) |
|------------------------|-----------------|-----------------|
| UPDRS totals | | |
| preop | 102/113 | 77/97 |
| postop | 63/72 | 66/71 |
| Schwab & England scale | | |
| preop | 70/60 | 90/80 |
| postop | 90/70 | 70/60 |
| Hoehn & Yahr scale | | |
| preop | 3/4 | 2.5/2.5 |
| postop | 3/3 | 2.5/3 |
| percentage of time off | | |
| preop | 50 | 50 |
| postop | 25 | 25 |

clear how GDNF exerts its beneficial effects, it likely involves interaction with the recently discovered GDNF receptor, which has been shown to exist in the adult substantia nigra.³⁶

Dopaminergic cell survival has been highest when fresh tissue is used for grafts in animal models^{2,6,18} and in most clinical implantation programs either fresh tissue or tissue stored for up to 48 hours before the procedure is used.^{5,11,19,27} In this study we have demonstrated that the addition of GDNF during storage promotes survival of TH-positive neurons of human fetal VM tissue for up to 6 days. This observation is particularly relevant for clinical implantation. Increasing the storage time before implantation allows time for collection of sufficient tissue for the procedure, which is important because there is a limited supply of human fetal tissue. Increasing the storage time to 6 days is essential for completion of serological and microbiological testing to ensure that no infected material is implanted in the recipient.

At present, the only valid method of assessing graft survival in vivo is by using PET scanning to measure fluorodopa uptake. Fluorodopa is an analog of levodopa that crosses the BBB and is stored in the nigrostriatal dopaminergic terminals. Correlations of graft survival and fluorodopa uptake on PET scans have been made by post-mortem examination of a patient who received fetal VM tissue 18 months before dying of causes unrelated to the implant procedure.¹³ Increases in the mean putaminal fluorodopa uptake reported in patients receiving fetal VM implants have been on the order of 61% when tissue from three to four donated fetuses is implanted per side.^{10,27} Further increases in fluorodopa uptake have been observed with higher numbers of donated fetuses. In a recent report on patients receiving unilateral grafts from four to seven donated fetuses, a mean increase of 68% in fluorodopa uptake was observed.³⁸ Five of these patients subsequently received a second graft in the contralateral putamen of tissue from four to eight donated fetuses 10 to 56 months after the first graft. The second graft produced a mean putaminal increase in fluorodopa uptake of 85% at 12 to 18 months after its implantation.⁹

The mean increase in putaminal fluorodopa uptake in the two patients reported here was 107% at 12 months postgrafting. The increase in fluorodopa uptake compares favorably with other studies,^{9,10,27,38} taking into account that

tissue from three donated fetuses per side was implanted in Case 1 and the patient in Case 2 received tissue from three fetuses on one side and four on the contralateral side. This observation indicates that exposure of fetal VM tissue to GDNF for 6 days was beneficial to graft survival in these two patients. A gradient of fluorodopa uptake was found in the grafted striata. The increase in fluorodopa uptake was 149.7% within the grafts, followed by an increase of 107% in the entire putamen and a 52.3% in the caudate. This gradual decline of fluorodopa uptake from the grafts to the host putamen and caudate may be related to fiber outgrowth. This finding correlates well with the previous observations in rats that received grafts of cell stored in GDNF, in which the density of TH-positive fibers decreased with distance from the graft.^{1,20}

Although clinical improvement was observed in both patients, a direct comparison with other studies is difficult because of the variability of methodology used in different studies and the small numbers reported here. Nevertheless, the clinical improvement observed in our two patients is similar to that seen in other studies in which evidence of graft survival has been demonstrated on PET scans.^{9,10,27,38}

Conclusions

In summary, we have provided evidence that exposure of human VM tissue to GDNF for 6 days promotes survival of stored human dopaminergic tissue. Extending the time of preservation of human fetal VM tissue is essential for tissue collection and microbiological screening. Furthermore, the use of GDNF during the storage period may have a role in enhancing graft survival and fiber outgrowth.

References

1. Apostolides C, Sanford E, Hong M, et al: Glial cell line-derived neurotrophic factor improves intrastriatal graft survival of stored dopaminergic cells. *Neuroscience* **83**:363–372, 1998
2. Brundin P, Isacson O, Björklund A: Monitoring of cell viability in suspensions of embryonic CNS tissue and its use as a criterion for intracerebral graft survival. *Brain Res* **331**:251–259, 1985
3. Evans AC, Marrett S, Torresscorzo J, et al: MRI-PET correlation in three dimensions using a volume-of-interest (VOI) atlas. *J Cereb Blood Flow Metab* **11**:A69–A78, 1991
4. Fahn S, Elton RL, Members of the UPDRS Development Committee: Unified Parkinson's Disease Rating Scale, in Fahn S, Marsden CD, Goldstein M, et al (eds): *Recent Developments in Parkinson's Disease*, ed 2. NY: Macmillan, 1987, pp 153–163
5. Freeman TB, Olanow CW, Hauser RA, et al: Bilateral fetal nigral transplantation into the postcommissural putamen in Parkinson's disease. *Ann Neurol* **38**:379–388, 1995
6. Frodl EM, Duan WM, Sauer H, et al: Human embryonic dopamine neurons xenografted to the rat: effects of cryopreservation and varying regional source of donor cells on transplant survival, morphology and function. *Brain Res* **647**:286–298, 1994
7. Gash DM, Zhang Z, Ovidia A, et al: Functional recovery in parkinsonian monkeys treated with GDNF. *Nature* **380**:252–255, 1996
8. Granholm AC, Mott JL, Bowenkamp K, et al: Glial cell line-derived neurotrophic factor improves survival of ventral mesencephalic grafts to the 6-hydroxydopamine lesioned striatum. *Exp Brain Res* **116**:29–38, 1997

9. Hagell P, Schrag A, Piccini P, et al: Sequential bilateral transplantation in Parkinson's disease. Effects of the second graft. **Brain** **122**:1121–1132, 1999
10. Hauser RA, Freeman TB, Snow BJ, et al: Long-term evaluation of bilateral fetal nigral transplantation in Parkinson disease. **Arch Neurol** **56**:179–187, 1999
11. Kopyov OV, Jacques DS, Lieberman A, et al: Outcome following intrastriatal fetal mesencephalic grafts for Parkinson's patients is directly related to the volume of grafted tissue. **Exp Neurol** **146**:536–545, 1997
12. Kordower JH, Freeman TB, Chen EY, et al: Fetal nigral grafts survive and mediate clinical benefit in a patient with Parkinson's disease. **Mov Disord** **13**:383–393, 1998
13. Kordower JH, Freeman TB, Snow BJ, et al: Neuropathological evidence of graft survival and striatal reinnervation after the transplantation of fetal mesencephalic tissue in a patient with Parkinson's disease. **N Engl J Med** **332**:1118–1124, 1995
14. Kordower JH, Rosenstein JM, Collier TJ, et al: Functional fetal nigral grafts in a patient with Parkinson's disease: chemoanatomic, ultrastructural, and metabolic studies. **J Comp Neurol** **370**:203–230, 1996
15. Langston JW, Widner H, Goetz CG, et al: Core assessment program for intracerebral transplantations (CAPIT). **Mov Disord** **7**:2–13, 1992
16. Leenders KL, Salmon EP, Tyrrell P, et al: The nigrostriatal dopaminergic system assessed in vivo by positron emission tomography in healthy volunteer subjects and patients with Parkinson's disease. **Arch Neurol** **47**:1290–1298, 1990
17. Lin LFH, Doherty DH, Lile JD, et al: GDNF: a glial cell line-derived neurotrophic factor for midbrain dopaminergic neurons. **Science** **260**:1130–1132, 1993
18. Lindvall O, Sawle G, Widner H, et al: Evidence for long-term survival and function of dopaminergic grafts in progressive Parkinson's disease. **Ann Neurol** **35**:172–180, 1994
19. Lindvall O, Widner H, Rehncrona S, et al: Transplantation of fetal dopamine neurons in Parkinson's disease: one-year clinical and neurophysiological observations in two patients with putaminal implants. **Ann Neurol** **31**:155–165, 1992
20. Mehta V, Hong M, Spears J, et al: Enhancement of graft survival and sensorimotor behavioral recovery in rats undergoing transplantation with dopaminergic cells exposed to glial cell line-derived neurotrophic factor. **J Neurosurg** **88**:1088–1095, 1998
21. Mehta V, Spears J, Mendez I: Neural transplantation in Parkinson's disease. **Can J Neurol Sci** **24**:292–301, 1997
22. Nakao N, Frodl EM, Duan WM, et al: Lazaroids improve the survival of grafted rat embryonic dopamine neurons. **Proc Natl Acad Sci USA** **91**:12408–12412, 1994
23. Nikkhah G, Cunningham MG, Jödicke A, et al: Improved graft survival and striatal reinnervation by microtransplantation of fetal nigral cell suspensions in the rat Parkinson model. **Brain Res** **633**:133–143, 1994
24. Olanow CW, Kordower JH, Freeman TB: Fetal nigral transplantation as a therapy for Parkinson's disease. **Trends Neurosci** **19**:102–109, 1996
25. Opacka-Juffry J, Ashworth S, Hume SP, et al: GDNF protects against 6-OHDA nigrostriatal lesion: in vivo study with microdialysis and PET. **Neuroreport** **7**:348–352, 1995
26. Patlak CS, Blasberg RG: Graphical evaluation of blood-to-brain transfer constants from multiple-time uptake data. Generalizations. **J Cereb Blood Flow Metab** **5**:584–590, 1985
27. Peschanski M, Defer G, N'Guyen JP, et al: Bilateral motor improvement and alteration of L-dopa effect in two patients with Parkinson's disease following intrastriatal transplantation of foetal ventral mesencephalon. **Brain** **117**:487–499, 1994
28. Rehncrona S: A critical review of the current status and possible developments in brain transplantation. **Adv Tech Stand Neurosurg** **23**:3–46, 1997
29. Remy P, Samson Y, Hantraye P, et al: Clinical correlates of [¹⁸F] Fluorodopa uptake in five grafted parkinsonian patients. **Ann Neurol** **38**:580–588, 1995
30. Sauer H, Brundin P: Effects of cool storage on survival and function of intrastriatal ventral mesencephalic grafts. **Restor Neurol Neurosci** **2**:123–135, 1991
31. Schierle GS, Hansson O, Leist M, et al: Caspase inhibition reduces apoptosis and increases survival of nigral transplants. **Nat Med** **5**:97–100, 1999
32. Sinclair SR, Svendsen CN, Torres EM, et al: GDNF enhances dopaminergic cell survival and fibre outgrowth in embryonic nigral grafts. **Neuroreport** **7**:2547–2552, 1996
33. Tabbal S, Fahn S, Fruct S: Fetal tissue transplantation in Parkinson's disease. **Curr Opin Neurol** **11**:341–349, 1998
34. Takayama H, Ray J, Raymon HK, et al: Basic fibroblast growth factor increases dopaminergic graft survival and function in a rat model of Parkinson's disease. **Nat Med** **1**:53–58, 1995
35. Tang FI, Tien LT, Zhou FC, et al: Intranigral ventral mesencephalic grafts and nigrostriatal injections of glial cell line-derived neurotrophic factor restore dopamine release in the striatum of 6-hydroxydopamine-lesioned rats. **Exp Brain Res** **119**:287–296, 1998
36. Treanor JJS, Goodman L, de Sauvage F, et al: Characterization of a multicomponent receptor for GDNF. **Nature** **382**:80–83, 1996
37. Vingerhoets JG, Schulzer M, Snow BJ: Reproducibility of the fluorodopa positron emission tomography indices in Parkinson's disease. **Mov Disord** **9** (Suppl 1):119, 1994 (Abstract)
38. Wenning GK, Odin P, Morrish P, et al: Short- and long-term survival and function of unilateral intrastriatal dopaminergic grafts in Parkinson's disease. **Ann Neurol** **42**:95–107, 1997
39. Yurek DM: Glial cell line-derived neurotrophic factor improves survival of dopaminergic neurons in transplants of fetal ventral mesencephalic tissue. **Exp Neurol** **153**:195–202, 1998
40. Yurek DM, Lu W, Hipkens S, et al: BDNF enhances the functional reinnervation of the striatum by grafted fetal dopamine neurons. **Exp Neurol** **137**:105–118, 1996
41. Zawada WM, Zastrow DJ, Clarkson ED, et al: Growth factors improve immediate survival of embryonic dopamine neurons after transplantation into rats. **Brain Res** **786**:96–103, 1998

Manuscript received November 8, 1999.

Address reprint requests to: Ivar Mendez, M.D., Ph.D., Division of Neurosurgery, QEII Health Sciences Centre, New Halifax Infirmary, 1796 Summer Street, Room #3806, Halifax, Nova Scotia, B3H 3A7, Canada. email: mendez@is.dal.ca.